CRQ Six

Bone Cement

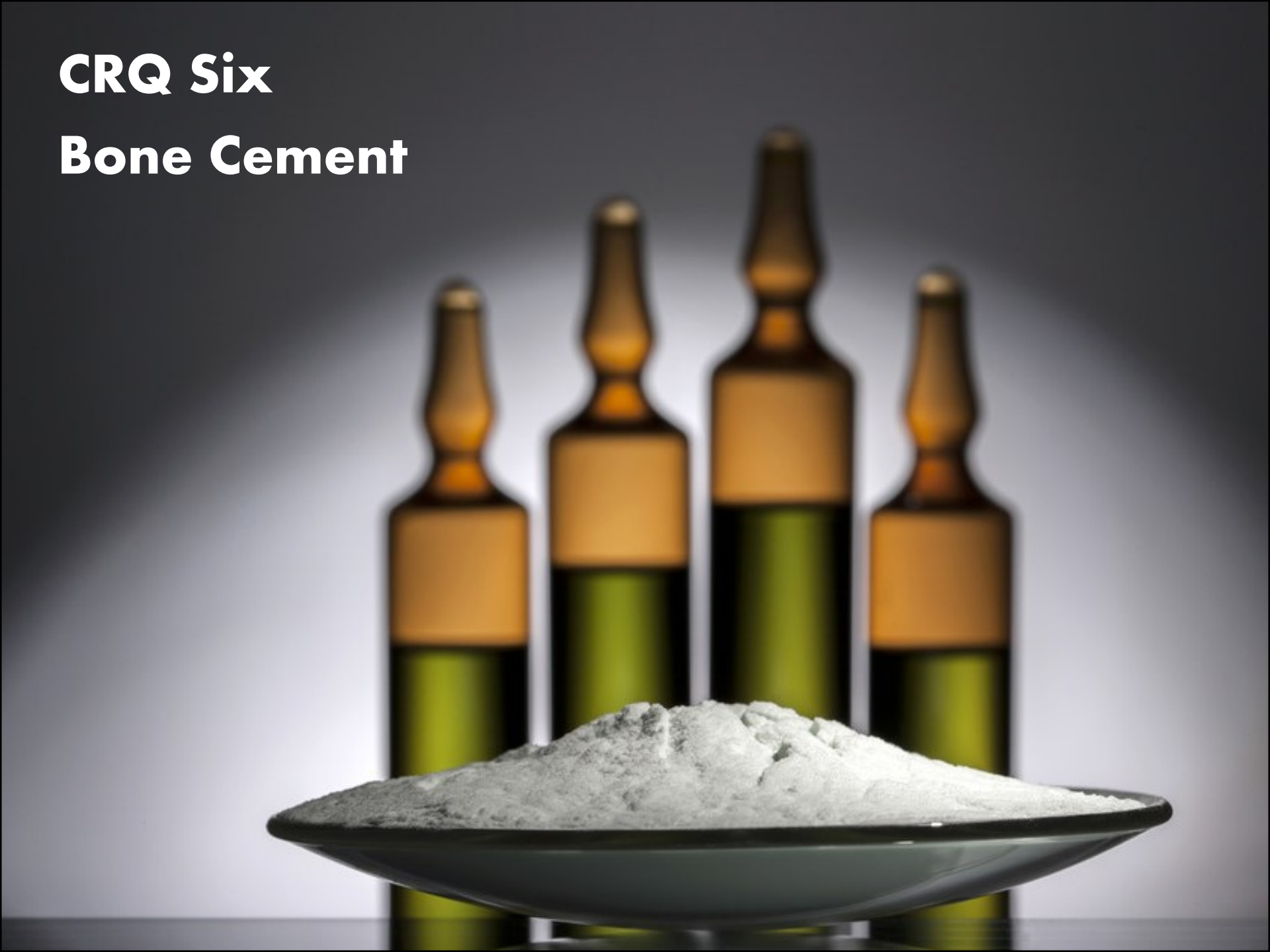

The medical orthopaedic use of PMMA is universally credited to Sir John Charnley.

He was inspired by his dentist to use dental acrylic for prosthetic fixation in THR procedures in 1957.

In 1965, he began to use bone cement developed specifically for THRs.

Sir John Charnley

Bone Cement

You are asked to anaesthetise an 85-year-old patient who had a mechanical fall at home and sustained a hip fracture. He is listed for a cemented hemiarthroplasty of his hip.

a) List two advantages that a cemented hip hemiarthroplasty has compared to an uncemented prosthesis (2 marks)

- **Increases the likelihood of pain-free mobility after surgery**
- **Reduces the risk of re-operation**
- **Is associated with a lower mortality rate at 30 days**

Bone Cement

b) What is the primary ingredient of bone cement? (1 mark)

- **Poly (methyl methacrylate) PMMA**

c) List two other substances that are added to bone cement (2 mark)

- **Antibiotics**
- **Radiopaque Contrast**
- **Colouring – Chlorophyll**

Table 1 Composition of bone cement

Poly(methyl methacrylate) (PMMA) (90%)	Powder polymer: pre-polymerized PMMA
	Initiator: dibenzoylperoxide
	Liquid monomer (MMA)
	Activator: *N,N*-dimethyl-*p*-toluidine
Antibiotics	Gentamicin, tobramycin, clindamycin
Radiographic contrast material (10%)	Zirconium dioxide or barium sulphate

Bone Cement Implantation Syndrome

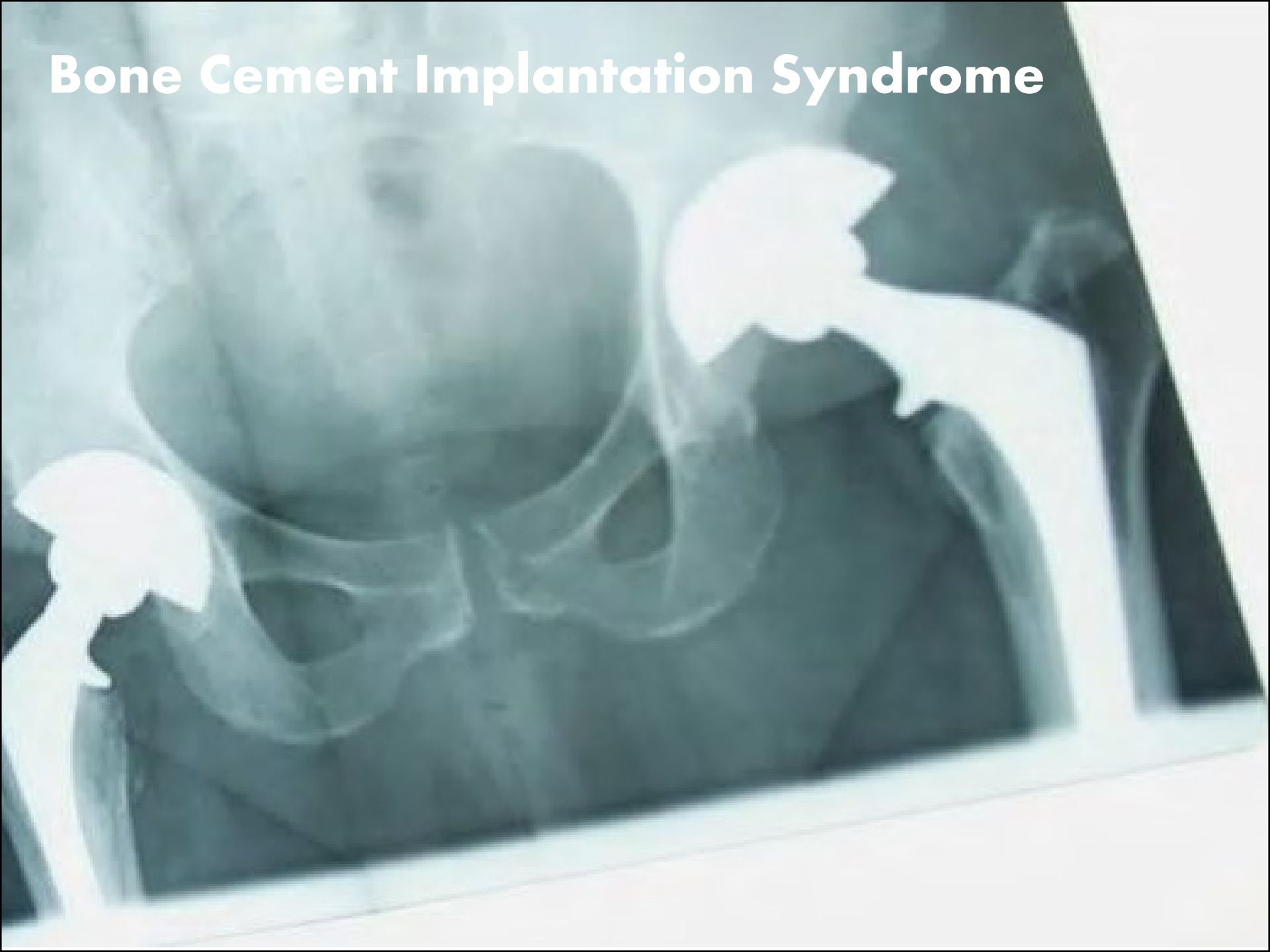

Bone Cement Implantation Syndrome

- Poorly understood phenomenon
- No agreed definition.
- An important cause of intraoperative mortality and morbidity
- Most commonly associated with cemented hip arthroplasty.

<u>The clinical features of BCIS typically occur at:</u>

- The time of cementation
- Prosthesis insertion
- Reduction in the joint
- Deflation of a limb tourniquet.

Bone Cement

d) List four risk factors that would indicate a patient was at high risk for cardiorespiratory compromise during cementing of a hip prosthesis (4 marks)

Patient Factors

- Increasing age
- ASA III-IV
- Significant cardiopulmonary disease
- Pre-existing pulmonary hypertension
- Diuretic use
- Male sex
- Osteoporosis

Surgical Factors

- Pathological fracture
- Intertrochanteric fracture
- Long stem arthroplasty

Bone Cement

e) Complete the table below which specifies the cardiorespiratory changes associated with different grades of bone cement implantation syndrome (BCIS) (4 marks)

	Arterial Oxygen Saturation	Percentage drop in Systolic Blood Pressure
Grade 1	**< 94%**	**> 20%**
Grade 2	**< 88%**	**> 40%**
Grade 3	Cardiopulmonary Resuscitation Required	

Bone Cement

f) Name the two models that have been proposed to explain the pathophysiological changes seen in BCIS (2 marks)

- **The monomer-mediated model**
- **The embolus-mediated model**

g) What is the common pathophysiological change explained by these models and thought to be the cause of the clinical picture seen in BCIS? (1 mark)

- **These mechanisms result in increased Pulmonary Vascular Resistance**

This is responsible for V/Q mismatch resulting in hypoxaemia.

Accept: Worsening pulmonary hypertension or right ventricular failure

Acute Right Heart Failure

- Sudden increase in Pulmonary Vascular Resistance [monomer/embolus related]
- Increased pulmonary artery pressure (PAP)
- The thin-walled and compliant right ventricle rapidly dilates and shifts the interventricular septum to the left thereby reducing the volume of the LV cavity.
- [The total volume of the heart cannot expand within such a rapid time frame, as it is constrained by the pericardium.]
- These changes cause an immediate decrease in left ventricular compliance, reduced ventricular filling, and cardiac output (CO).

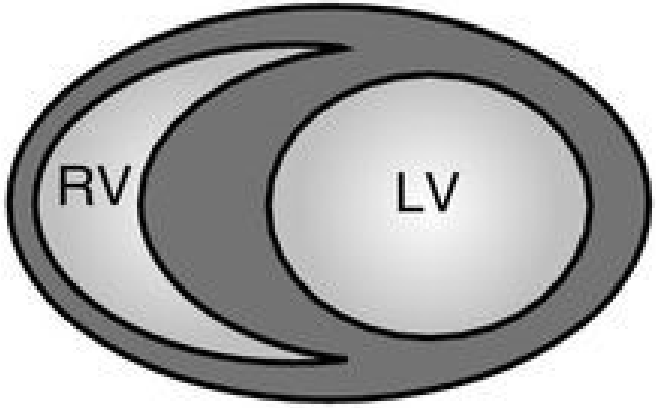

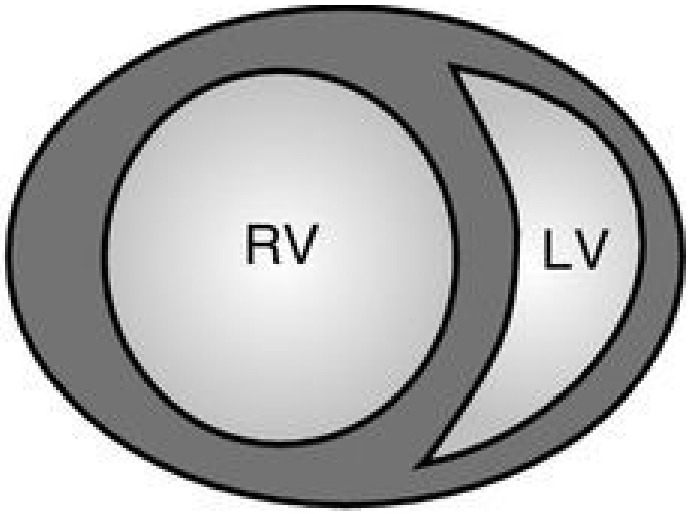

Bone Cement

g) Other than avoiding using cemented prostheses, list four ways in which a surgeon might reduce the risk of bone cement implantation syndrome (4 marks)

- Inform the anaesthetist that they are about to insert cement
- Thoroughly wash and dry the femoral canal
- Apply cement in retrograde fashion using the cement gun
- Insert a suction catheter and an intramedullary plug in the femoral shaft
- Avoid vigorous pressurisation of cement in patients judged to be at risk

Bone Cement

Bone cement and the implications for anaesthesia

Revalidation
FOR ANAESTHETISTS
RCA Revalidation matrix
Matrix reference 2A06, 3A08

Gautam Khanna FCARCSI, EDRA
Jan Cernovsky FRCA

Continuing Education in Anaesthesia, Critical Care & Pain | Volume 12 Number 4 2012

Bone Cement

Bone cement and the implications for anaesthesia

Gautam Khanna FCARCSI, EDRA
Jan Cernovsky FRCA

Continuing Education in Anaesthesia, Critical Care & Pain | Volume 12 Number 4 2012

Reducing the risk from cemented hemiarthroplasty for hip fracture 2015

Published by
The Association of Anaesthetists of Great Britain & Ireland
British Orthopaedic Association
British Geriatric Society

February 2015

Table 2 Specific intra-operative surgical and anaesthetic roles for reducing the incidence and management of BCIS.

Conduct of surgery	Ask the anaesthetist to confirm that he/she has heard your instruction to the theatre team that you are about to prepare the femoral canal for cement and prosthesis insertion
	Carefully prepare, wash and dry the femoral canal. Use of a pressurised lavage system is recommended to clean the endosteal bone of fat and marrow contents
	Use a distal suction catheter on top of an intramedullary plug. Insert the cement from a gun in retrograde fashion on top of the plug and pull the catheter out as soon as it is blocked with cement.
	Do not use excessive manual pressurisation or pressurisation devices in patients at higher risk of cardiovascular events (see above for risk factors)
Conduct of anaesthesia	Ensure that the patient is adequately hydrated before induction of and during anaesthesia
	Maintain vigilance for possible cardiovascular events once the femoral head is removed and the surgeon has verbally indicated his/her intent to instrument the femoral canal
	Confirm to the surgeon that you are aware of preparation of the femoral canal for cement and prosthesis insertion
	Aim to maintain the systolic blood pressure within 20% of pre-induction values throughout surgery, using vasopressors and/or fluids. Invasive blood pressure monitoring is indicated for patients at higher risk
	Be ready to give vasopressors, e.g. metaraminol/adrenaline in case of cardiovascular collapse

Table 2 Specific intra-operative surgical and anaesthetic roles for reducing the incidence and management of BCIS.

Conduct of surgery	Ask the anaesthetist to confirm that he/she has heard your instruction to the theatre team that you are about to prepare the femoral canal for cement and prosthesis insertion Carefully prepare, wash and dry the femoral canal. Use of a pressurised lavage system is recommended to clean the endosteal bone of fat and marrow contents Use a distal suction catheter on top of an intramedullary plug. Insert the cement from a gun in retrograde fashion on top of the plug and pull the catheter out as soon as it is blocked with cement. Do not use excessive manual pressurisation or pressurisation devices in patients at higher risk of cardiovascular events (see above for risk factors)

Conduct of anaesthesia	Ensure that the patient is adequately hydrated before induction of and during anaesthesia Maintain vigilance for possible cardiovascular events once the femoral head is removed and the surgeon has verbally indicated his/her intent to instrument the femoral canal Confirm to the surgeon that you are aware of preparation of the femoral canal for cement and prosthesis insertion Aim to maintain the systolic blood pressure within 20% of pre-induction values throughout surgery, using vasopressors and/or fluids. Invasive blood pressure monitoring is indicated for patients at higher risk Be ready to give vasopressors, e.g. metaraminol/adrenaline in case of cardiovascular collapse

Table 2 Specific intra-operative surgical and anaesthetic roles for reducing the incidence and management of BCIS.

Conduct of surgery	Ask the anaesthetist to confirm that he/she has heard your instruction to the theatre team that you are about to prepare the femoral canal for cement and prosthesis insertion
	Carefully prepare, wash and dry the femoral canal. Use of a pressurised lavage system is recommended to clean the endosteal bone of fat and marrow contents
	Use a distal suction catheter on top of an intramedullary plug. Insert the cement from a gun in retrograde fashion on top of the plug and pull the catheter out as soon as it is blocked with cement.
	Do not use excessive manual pressurisation or pressurisation devices in patients at higher risk of cardiovascular events (see above for risk factors)
Conduct of anaesthesia	Ensure that the patient is adequately hydrated before induction of and during anaesthesia
	Maintain vigilance for possible cardiovascular events once the femoral head is removed and the surgeon has verbally indicated his/her intent to instrument the femoral canal
	Confirm to the surgeon that you are aware of preparation of the femoral canal for cement and prosthesis insertion
	Aim to maintain the systolic blood pressure within 20% of pre-induction values throughout surgery, using vasopressors and/or fluids. Invasive blood pressure monitoring is indicated for patients at higher risk
	Be ready to give vasopressors, e.g. metaraminol/adrenaline in case of cardiovascular collapse

ELSEVIER

Revalidation FOR ANAESTHETISTS
RCoA Revalidation matrix
Matrix codes: 1A01, 2A06, 3A10

BJA Education, 21(9): 322–328 (2021)

doi: 10.1016/j.bjae.2021.04.003
Advance Access Publication Date: 6 July 2021

Fat embolism syndrome

D. Luff[1,*] and D.W. Hewson[1,2]

[1]Queen's Medical Centre, Nottingham University Hospitals NHS Trust, Nottingham, UK and [2]University of Nottingham, Nottingham, UK

*Corresponding author: delme.luff2@nuh.nhs.uk

Keywords: fat embolism syndrome; femoral fracture; perioperative medicine

SBA Practice
Fat Embolism

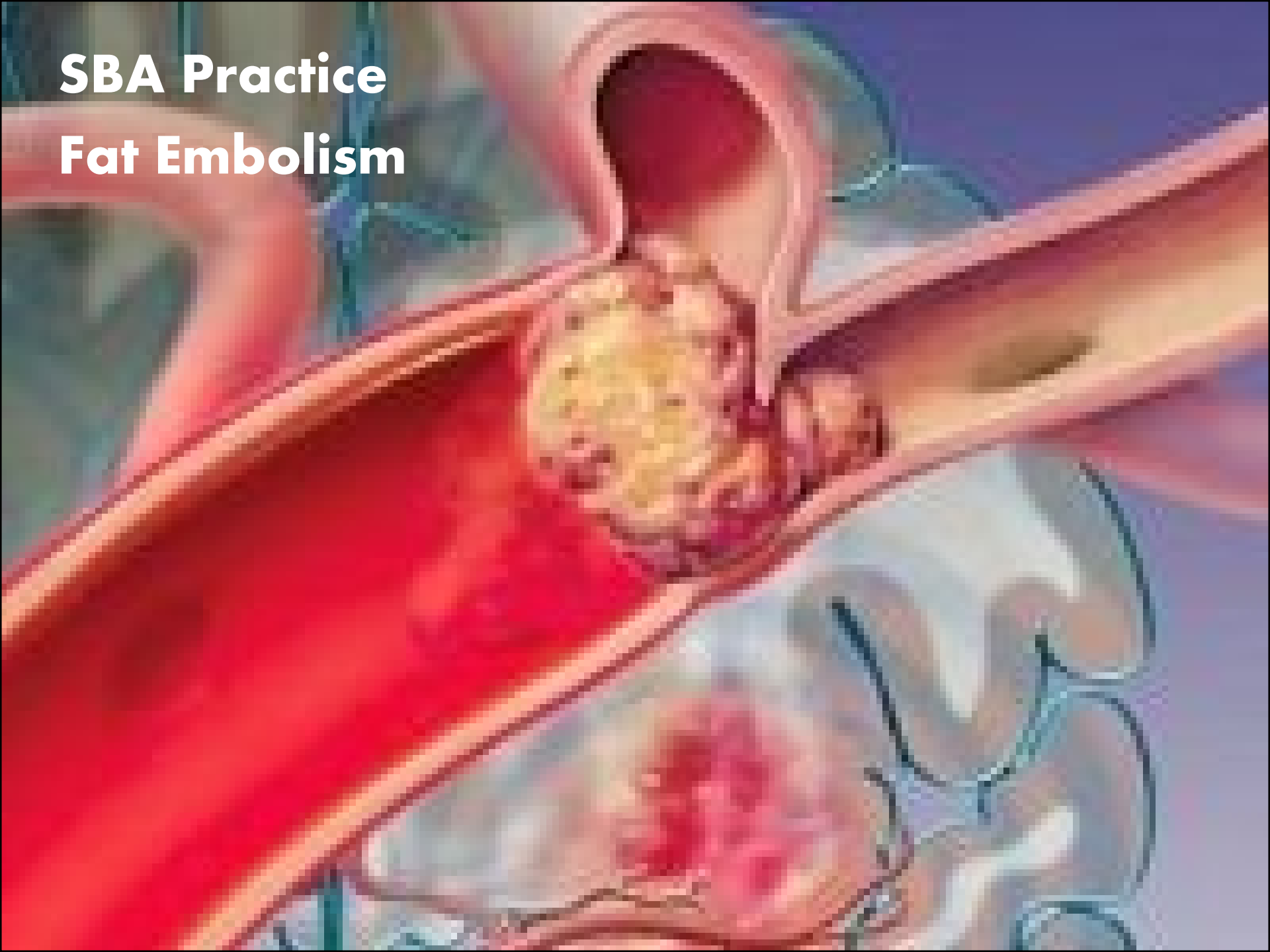

SBA One

A 25-year-old male patient is admitted with an isolated high energy femoral shaft fracture.

Which of the following statements is most accurate?

a. Fat Embolism Syndrome (FES) is defined as the presence of fat globules within the circulation.

b. There is unlikely to be evidence of fat globules in the blood of this patient at the time of admission to hospital.

c. Most patients with evidence of fat globules in the blood will go on to develop end organ failure.

d. Fat Embolism Syndrome is more common in children than in adults.

e. Even if the presenting features of Fat Embolism Syndrome are severe, the chance of a full recovery is high.

SBA One

A 25-year-old male patient is admitted with an isolated high energy femoral shaft fracture.

Which of the following statements is most accurate?

a. Fat Embolism Syndrome (FES) is defined as the presence of fat globules within the circulation.

b. There is unlikely to be evidence of fat globules in the blood of this patient at the time of admission to hospital.

c. Most patients with evidence of fat globules in the blood will go on to develop end organ failure.

d. Fat Embolism Syndrome is more common in children than in adults.

e. Even if the presenting features of Fat Embolism Syndrome are severe, the chance of a full recovery is high.

SBA Two

Which of the following best describes the presentation of Fat Embolism Syndrome (FES)?

a. The classic triad of respiratory distress, neurological dysfunction and petechial rash must occur for diagnosis of FES to be made.

b. The most common clinical finding is a petechial rash, which is present in more than 70% of cases.

c. Like Bone Cement Implantation Syndrome, FES often presents during surgery.

d. FES typically presents insidiously 24-72 hours after injury.

e. FES is always associated with trauma.

SBA Two

Which of the following best describes the presentation of Fat Embolism Syndrome (FES)?

a. The classic triad of respiratory distress, neurological dysfunction and petechial rash must occur for diagnosis of FES to be made.

b. The most common clinical finding is a petechial rash, which is present in more than 70% of cases.

c. Like Bone Cement Implantation Syndrome, FES often presents during surgery.

d. FES typically presents insidiously 24-72 hours after injury.

e. FES is always associated with trauma.

1

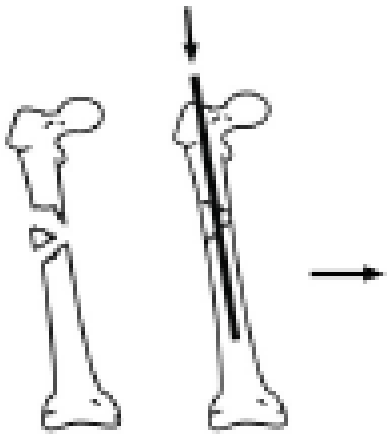

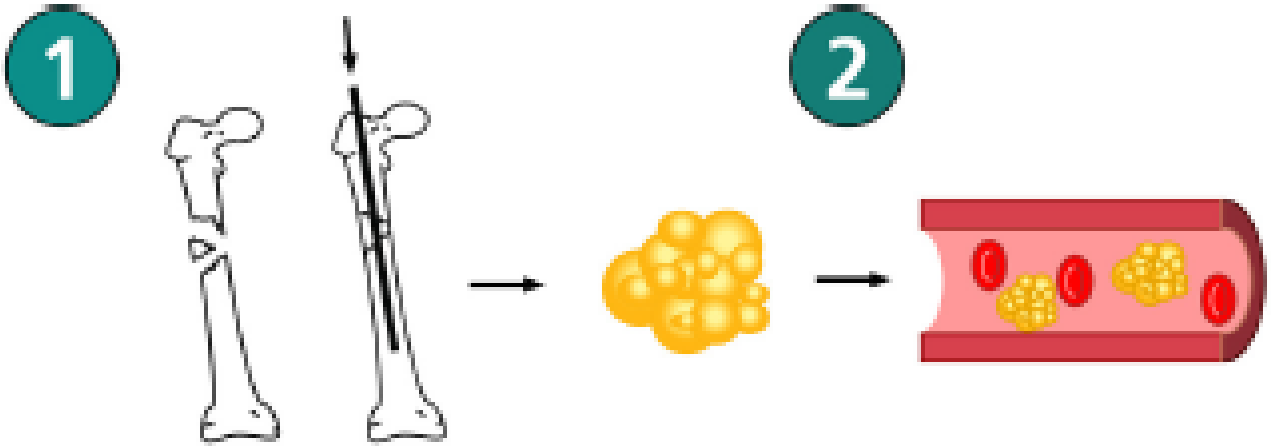
1
2

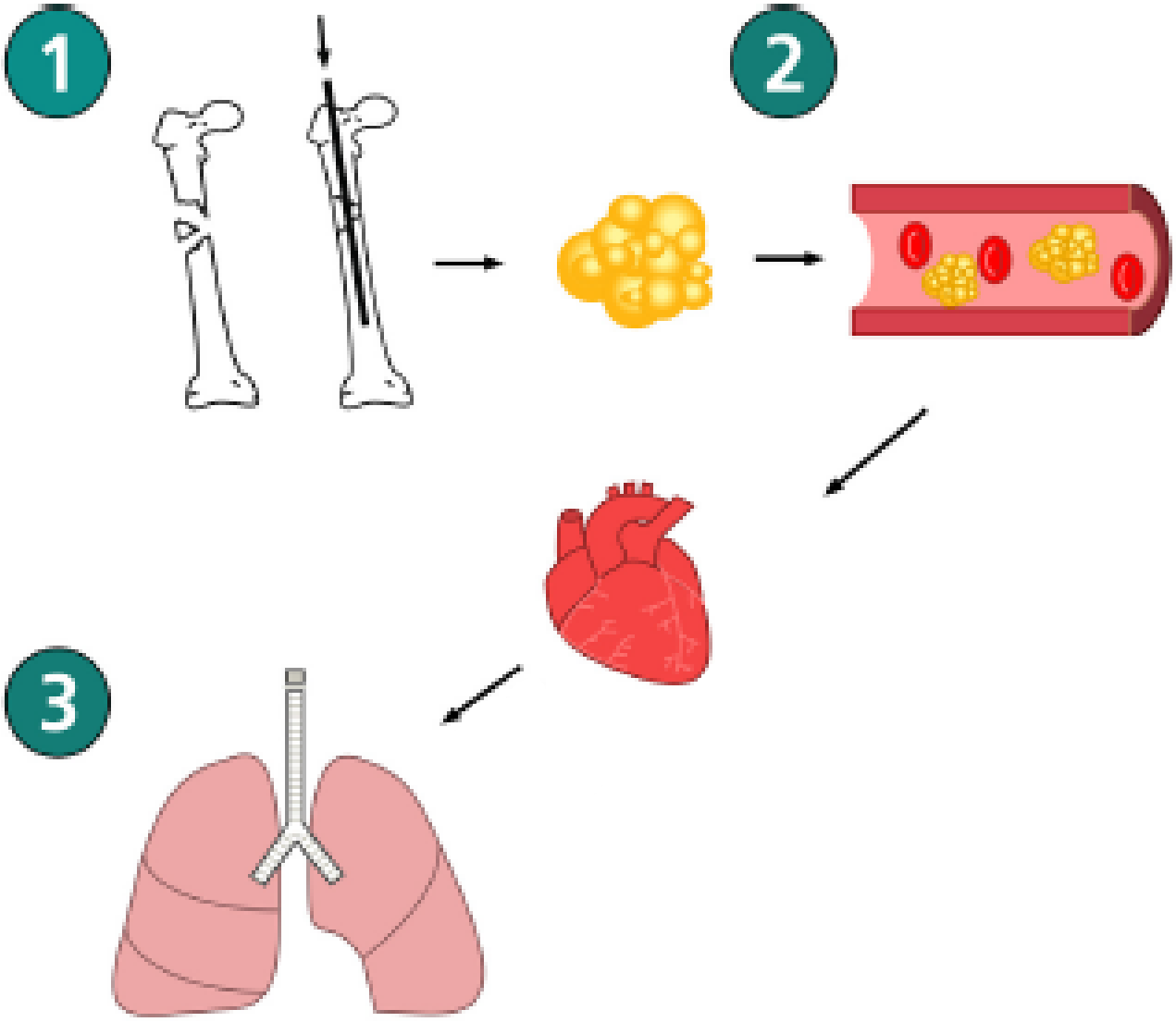
1
2
3

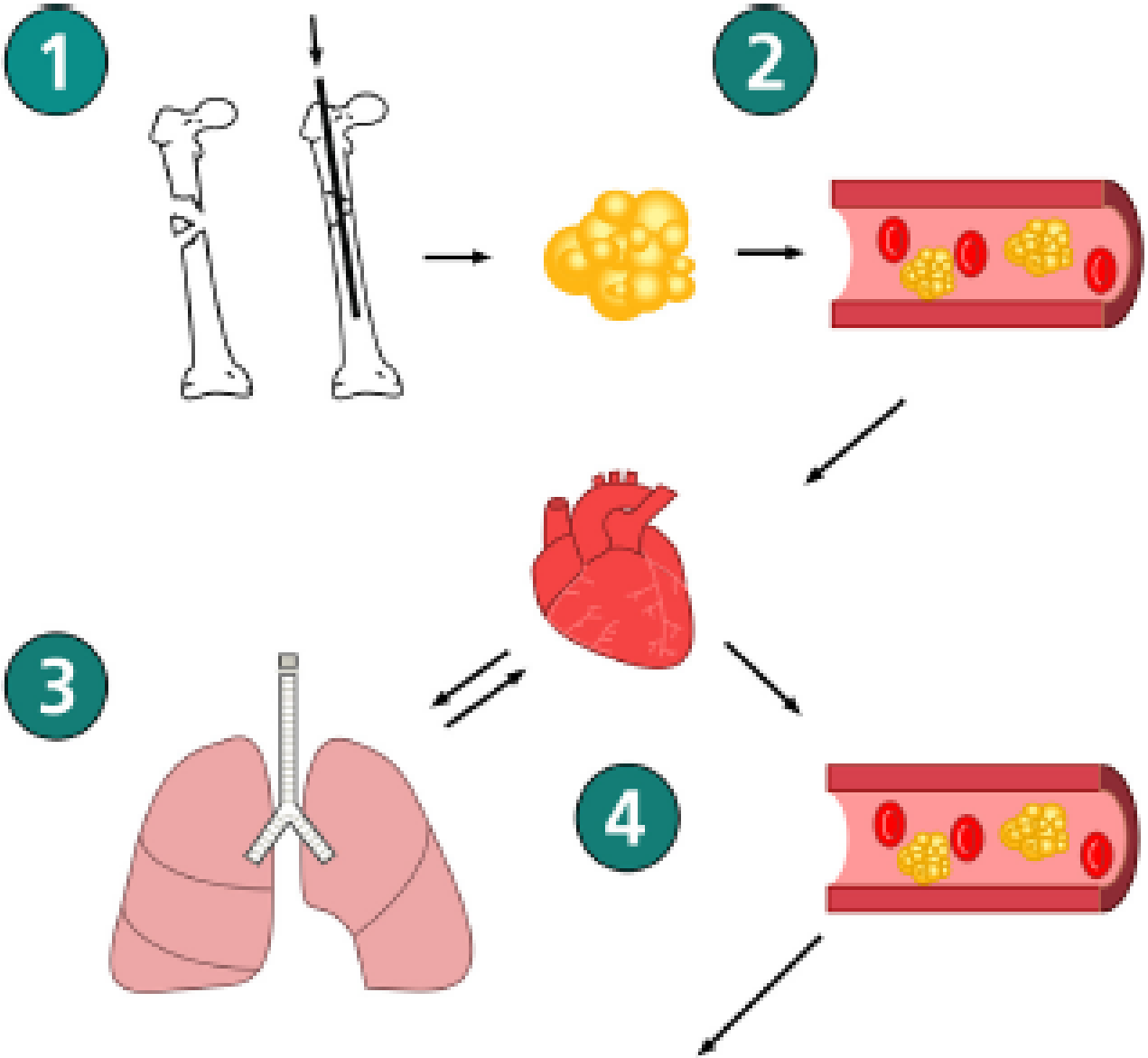
1
2
3
4

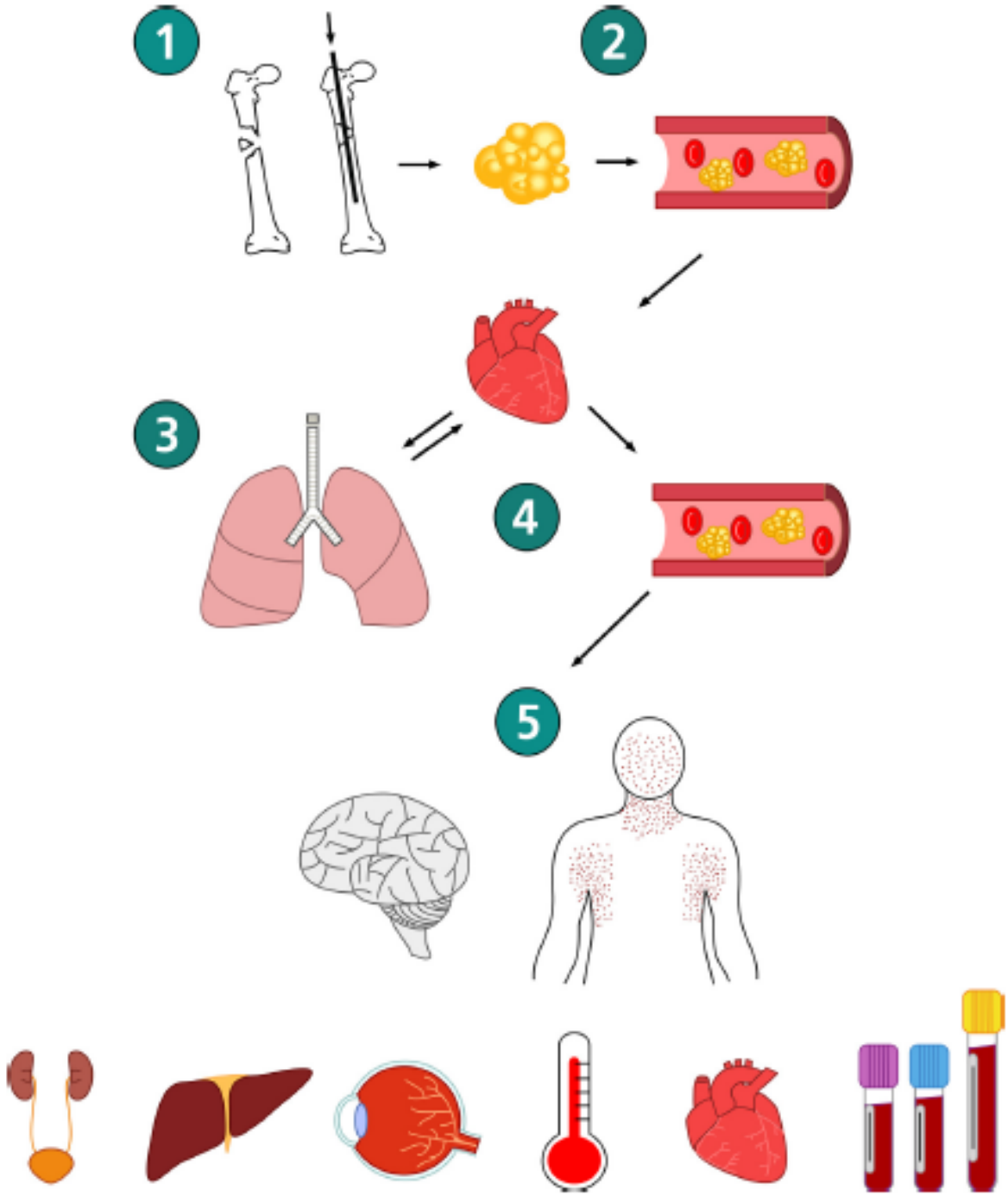
1
2
3
4
5

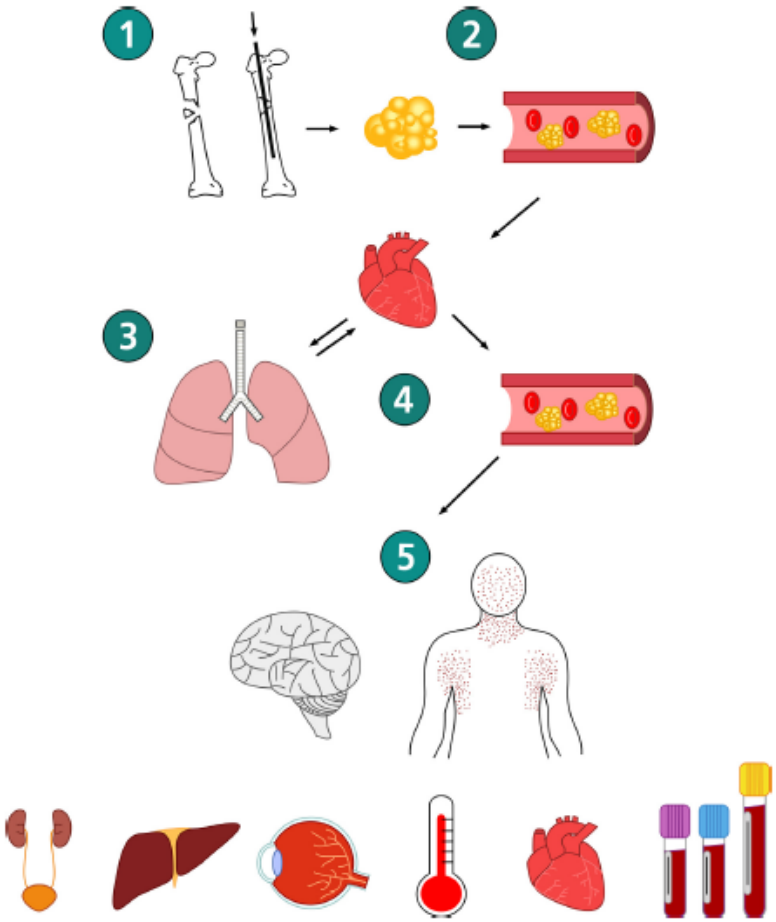

Table 1 Documented sequelae of fat embolism syndrome. ARDS, acute respiratory distress syndrome.

Respiratory	Tachypnoea Hypoxaemia ARDS
Neurological	Confusion Seizures Altered level of consciousness Focal neurological deficits
Dermatological	Petechial rash
Systemic	Fever
Cardiovascular	Tachycardia Hypotension Arrhythmia Myocardial ischaemia Pulmonary hypertension Right-sided heart failure
Ophthalmic	Purtscher's retinopathy (cotton wool exudates, macular oedema and haemorrhage)
Renal	Oliguria Proteinuria Lipiduria Haematuria
Hepatic	Jaundice
Haematological	Anaemia Thrombocytopenia Coagulopathy Fat macroglobulinaemia

SBA Three

Which is the most accurate statement regarding the diagnosis of Fat Embolism Syndrome (FES)?

a. Fundoscopy has no role in the diagnosis of FES.

b. The diagnostic criteria for FES are well validated.

c. Diagnosis of FES using Gurd's criteria requires the presence of one major criterion and two minor criteria.

d. The Full Blood Count can assist the diagnosis of FES.

e. The presence of fat globules in the sputum and urine is diagnostic of FES.

SBA Three

Which is the most accurate statement regarding the diagnosis of Fat Embolism Syndrome (FES)?

a. **Fundoscopy has no role in the diagnosis of FES.**

b. **The diagnostic criteria for FES are well validated.**

c. **Diagnosis of FES using Gurd's criteria requires the presence of one major criterion and two minor criteria.**

d. **The Full Blood Count can assist the diagnosis of FES.**

e. **The presence of fat globules in the sputum and urine is diagnostic of FES.**

Table 2 Gurd's diagnostic criteria. The presence of one major and four minor criteria were proposed as sufficient for a diagnosis of fat embolism syndrome.

Major criteria	Axillary or subconjunctival petechiae
	Hypoxaemia with bilateral radiographic changes
	Cerebral signs unrelated to head injury or any other condition
Minor criteria	Tachycardia
	Pyrexia
	Emboli present in the retina on fundoscopy
	Fat present in urine
	A sudden decrease in haematocrit or platelet concentrations
	Increasing erythrocyte sedimentation rate
	Fat globules present in the sputum

SBA Three

Whi m
Syn

a.

b.

c.

d.

e.

Table 2 Gurd's diagnostic criteria. The presence of one major and four minor criteria were proposed as sufficient for a diagnosis of fat embolism syndrome.

Major criteria	Axillary or subconjunctival petechiae
	Hypoxaemia with bilateral radiographic changes
	Cerebral signs unrelated to head injury or any other condition
Minor criteria	Tachycardia
	Pyrexia
	Emboli present in the retina on fundoscopy
	Fat present in urine
	A sudden decrease in haematocrit or platelet concentrations
	Increasing erythrocyte sedimentation rate
	Fat globules present in the sputum

Pathophysiology

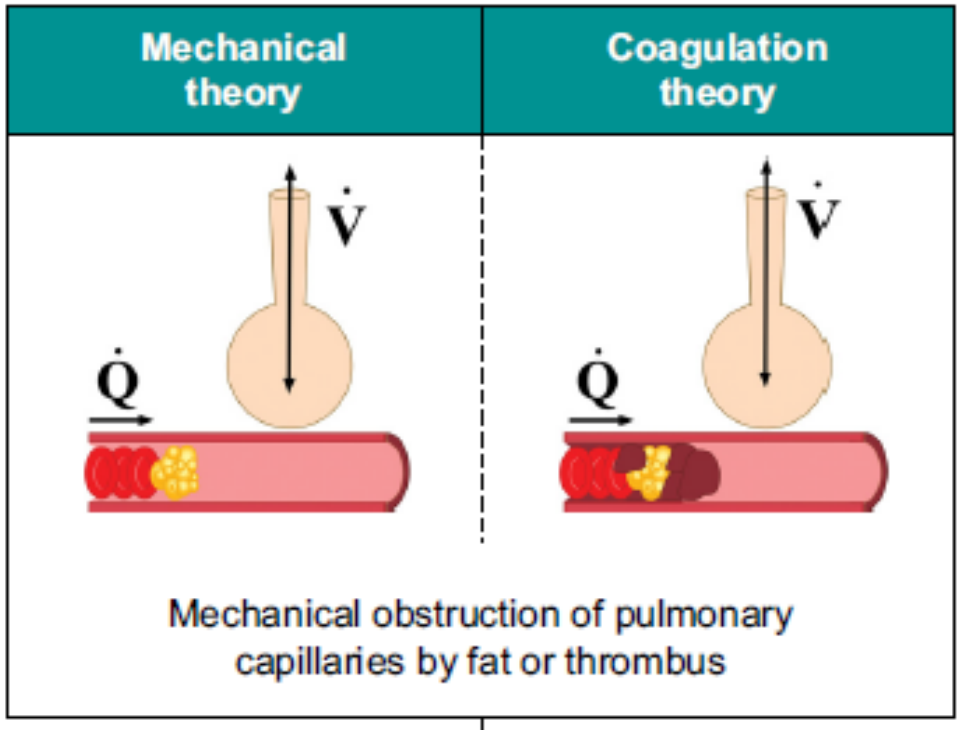

Pathophysiology

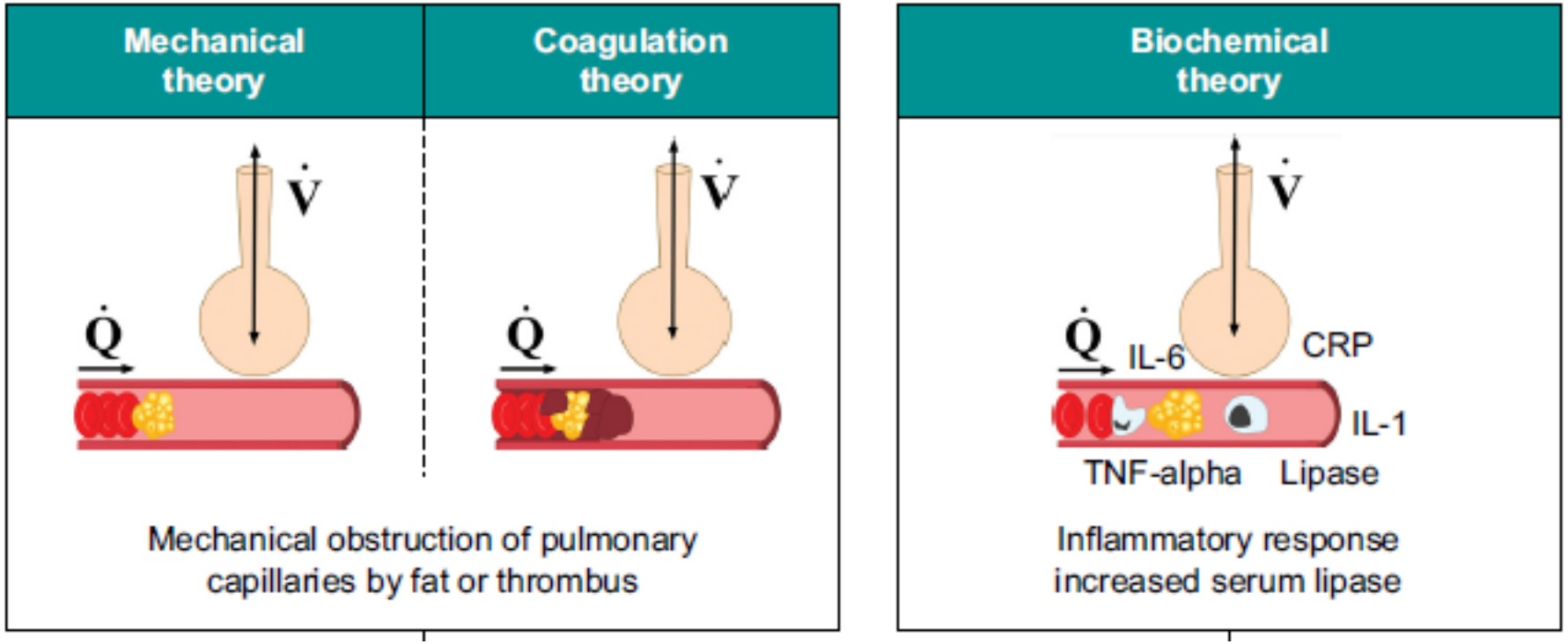

Pathophysiology

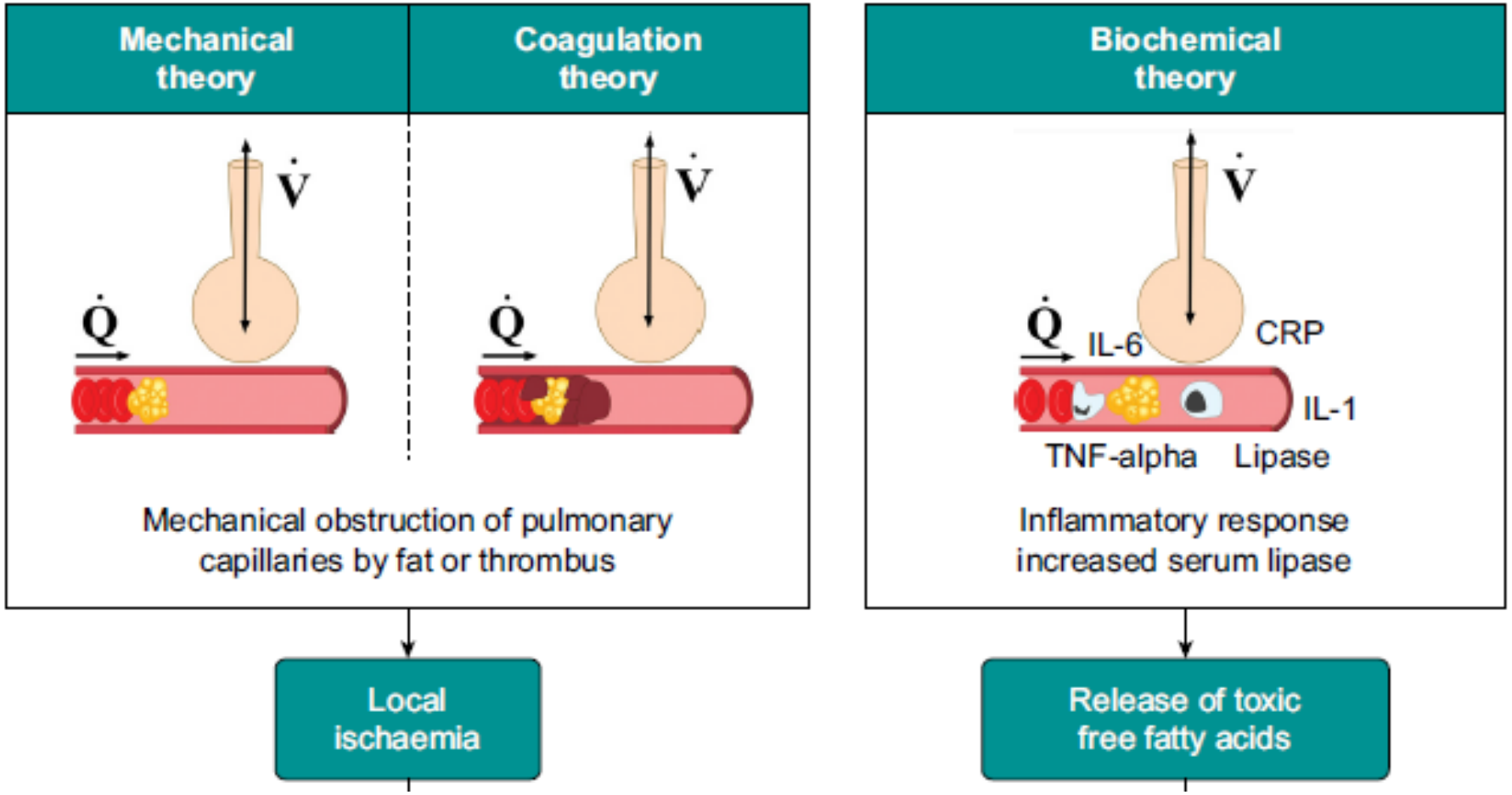

Pathophysiology

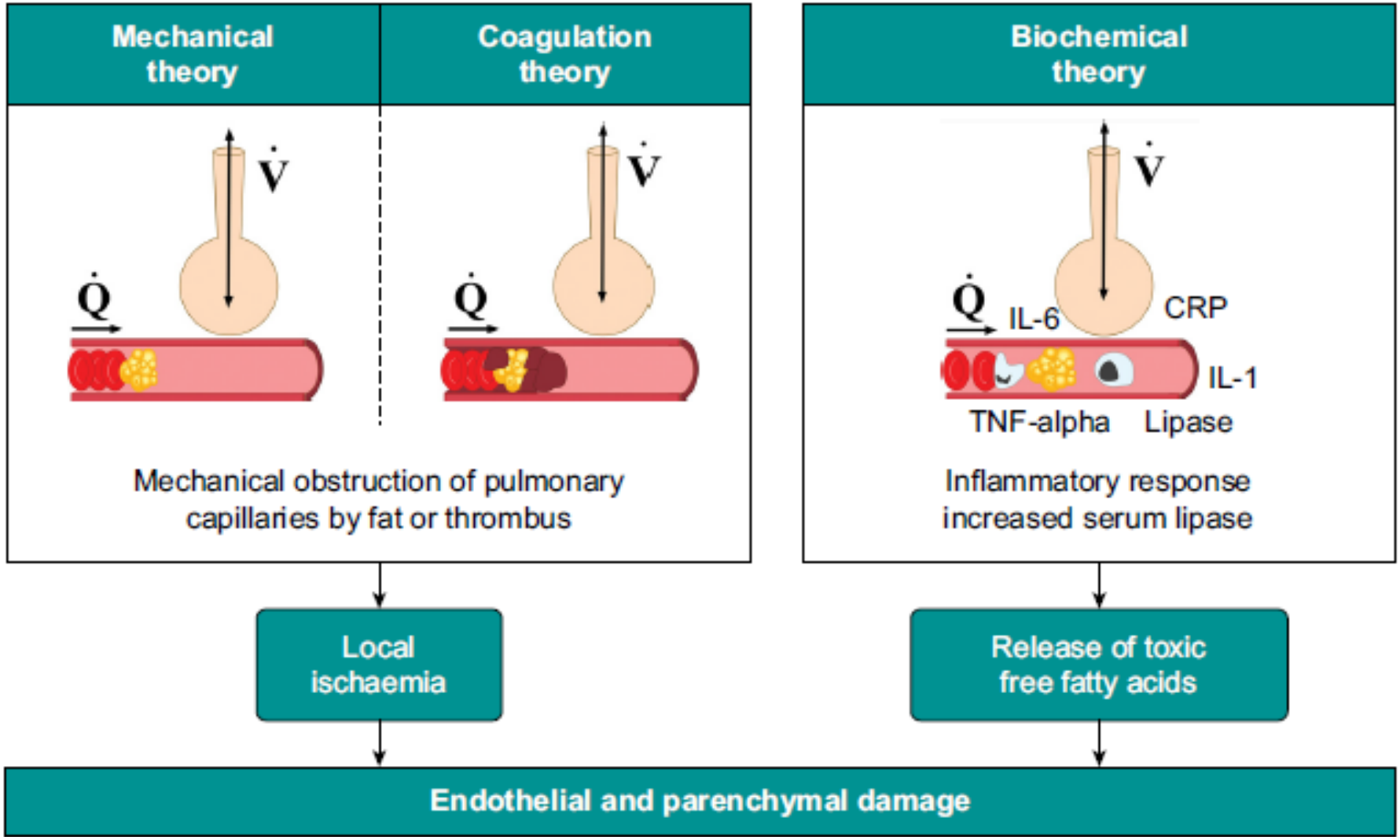

Pathophysiology

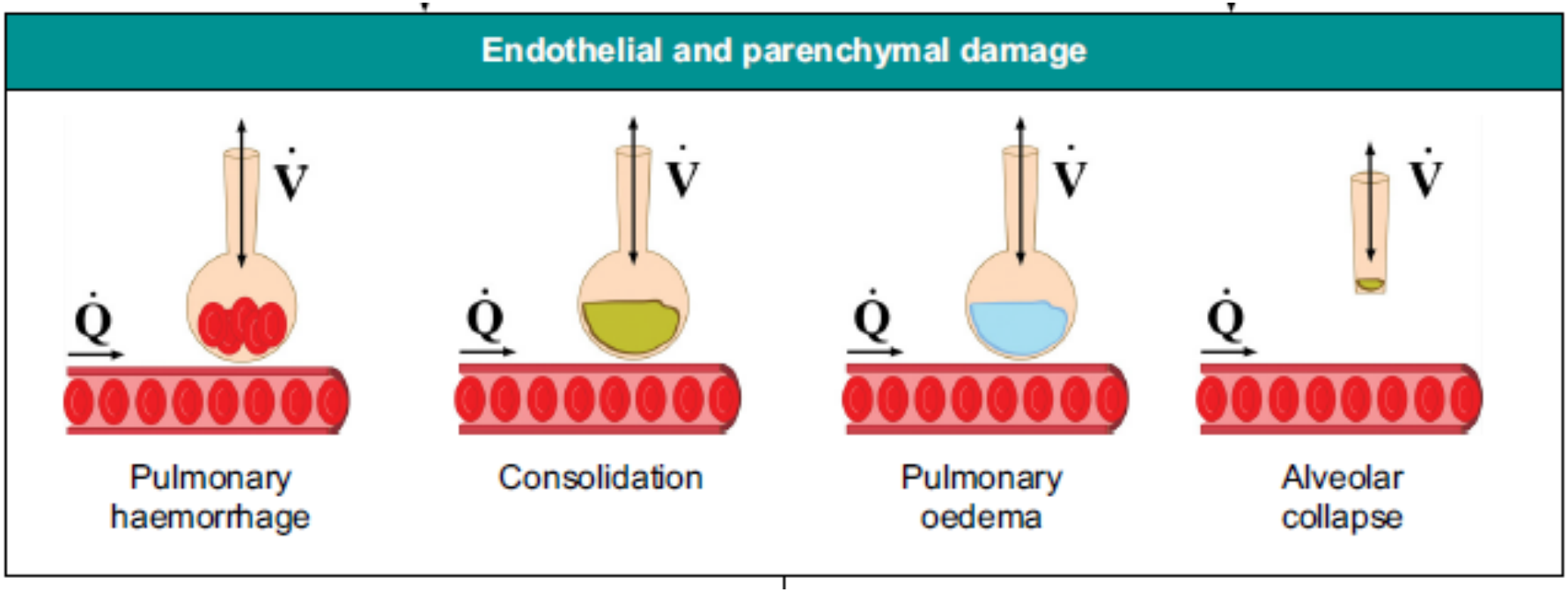

Pathophysiology

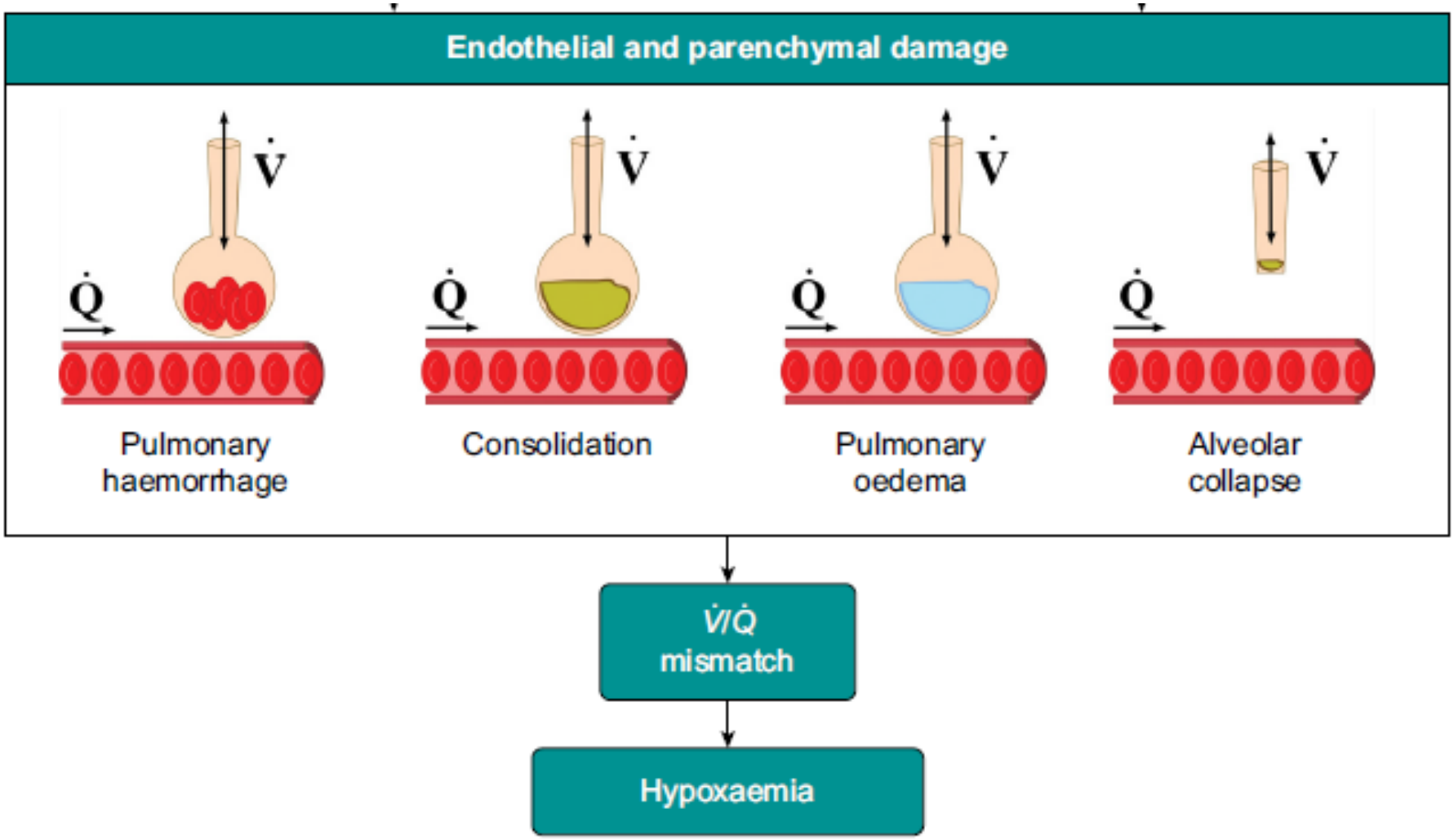

Pathophysiology

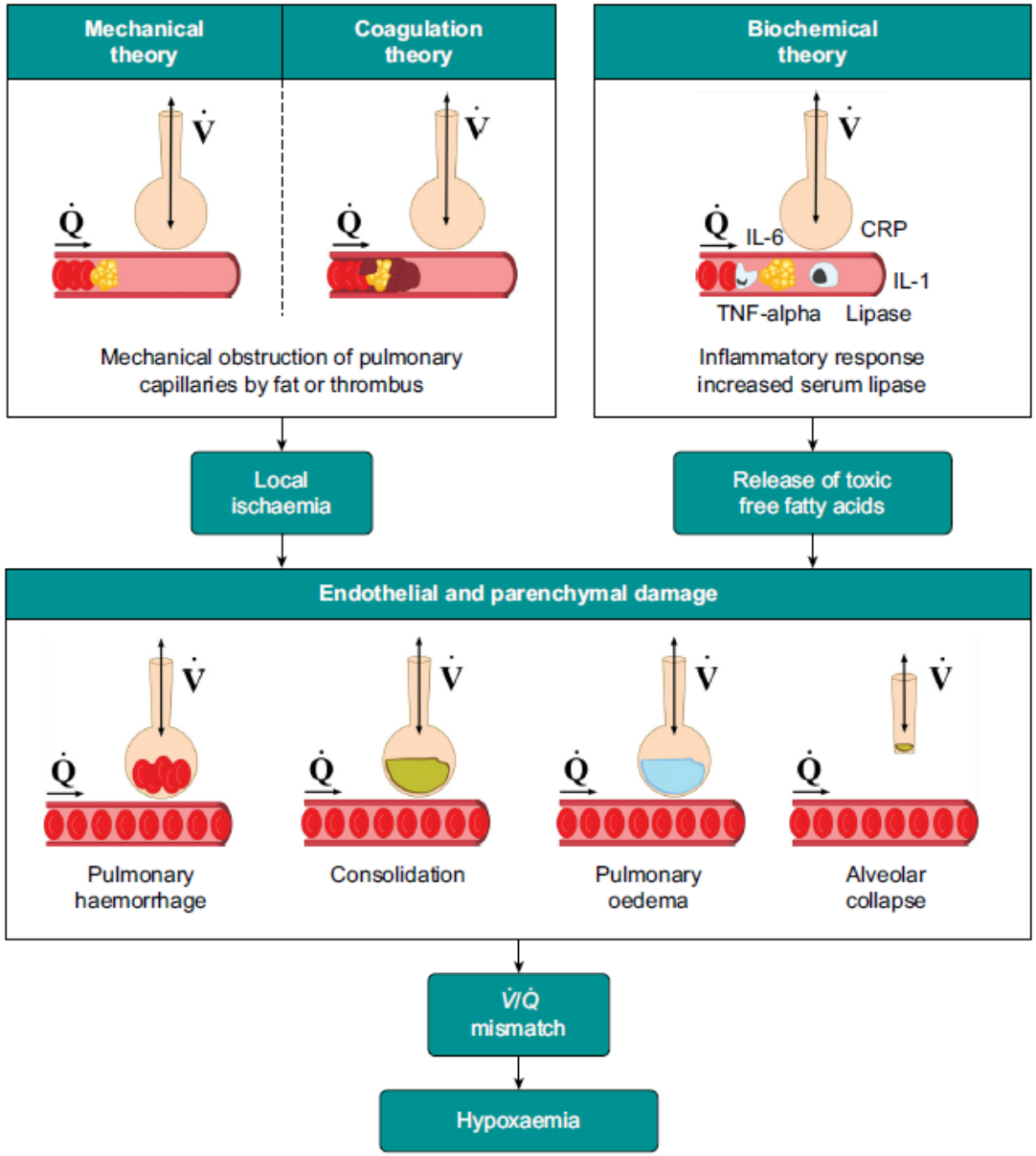

Management of FES

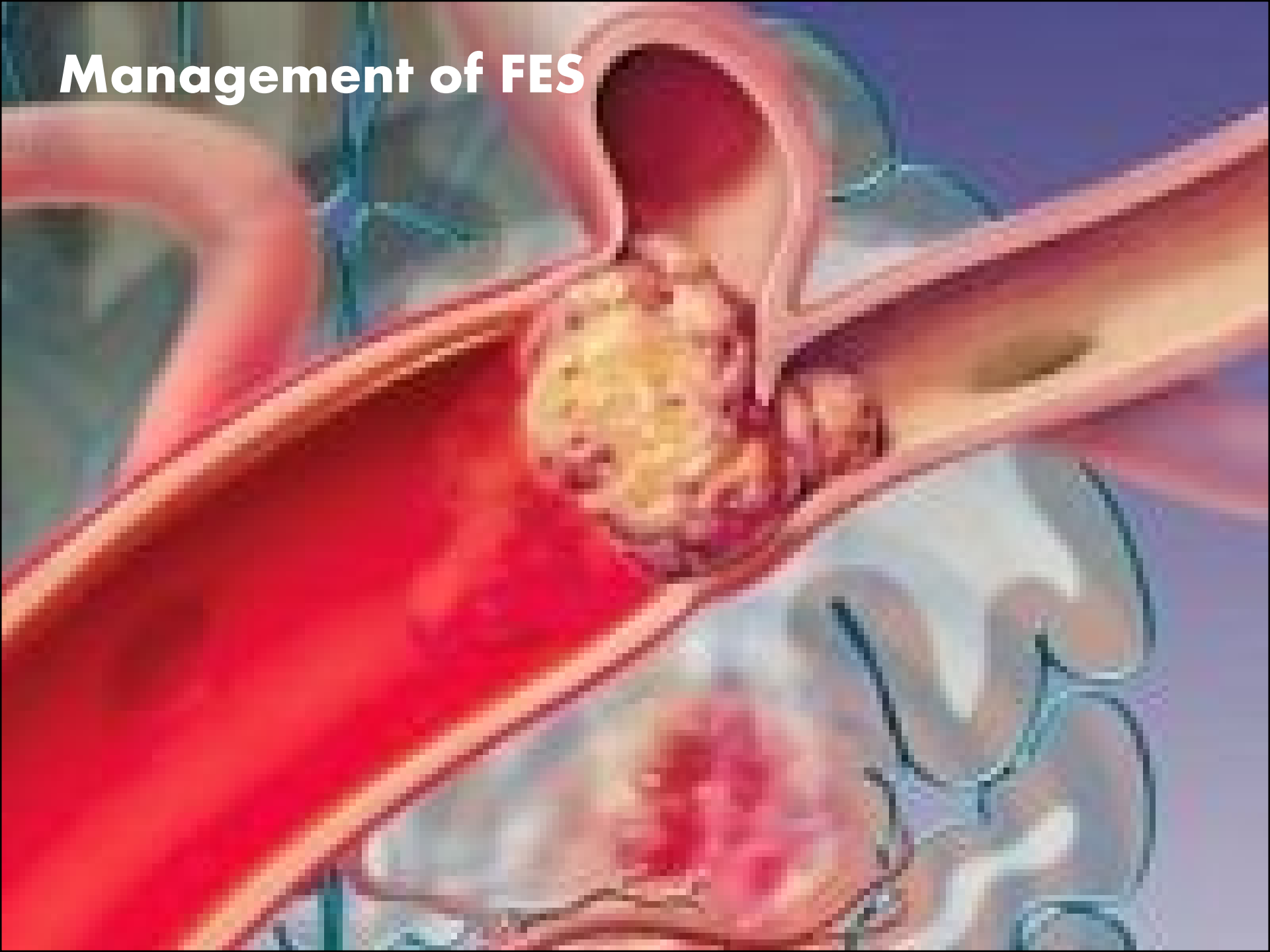

Management of FES

- Supportive management is the mainstay
- Critical Care admission may be warranted for monitoring of physiology and prompt management of deterioration
- Ventilatory Support (IPPV/NIV) in 10-40% of patients

<u>Specific Management</u>

- Early surgical fixation:
  - Internal plating/external fixator rather than IM Nailing
- Pharmacology:
  - Anticoagulation/Steroids
  - No evidence and competing risks

ELSEVIER

Revalidation FOR ANAESTHETISTS
RCoA Revalidation matrix
Matrix codes: 1A01, 2A06, 3A10

BJA Education, 21(9): 322–328 (2021)

doi: 10.1016/j.bjae.2021.04.003
Advance Access Publication Date: 6 July 2021

Fat embolism syndrome

D. Luff[1,*] and D.W. Hewson[1,2]

[1]Queen's Medical Centre, Nottingham University Hospitals NHS Trust, Nottingham, UK and [2]University of Nottingham, Nottingham, UK

*Corresponding author: delme.luff2@nuh.nhs.uk

Keywords: fat embolism syndrome; femoral fracture; perioperative medicine